



PATIENT

Mickey Morales

SPECIES

Feline

BREED

DSH

SEX

Male Neutered

AGE

9 years

WEIGHT

15lbs

INTERPRETED BY

Maggie Machen Lamy,
DVM, DACVIM
(Cardiology)

IMAGING PERFORMED BY

Elaina Petrone, DVM

HOSPITAL NAME

Long Branch Animal
Hospital

REFERRING VET

Dr. Petrone

INVOICE

45648

DATE

11/4/25

PRESENTING CLINICAL SIGNS

History: Presented for tachypnea, dyspnea, and lethargy. Marked ascites, mild pleural effusion, obvious dilated LA and RA. Started Lasix.

ECHOCARDIOGRAM FINDINGS

Limited 2D imaging set is provided. Moderate left ventricular dilation with diminished systolic function. The LV wall thickness is asymmetric, with mild septal thickening and a region of thinning. Marked left atrial enlargement with subtle smoke suspected. Severe right atrial dilation. Scant pericardial effusion noted. Pockets of pleural effusion and abdominal effusion noted. No obvious cardiac tumors. Irregular rapid rate and rhythm throughout.

CARDIAC CHART

FELINE CARDIAC PARAMETERS	BODY WEIGHT (kg)	HR (BPM)	IVSd (cm) (Moise, Pipers)	LVIDd (cm) (Moise, Pipers)	LVWd (cm) (Moise, Pipers)	FS (%)	EF (%)
NORMAL PARAMETER	-----	150-240	0.35-0.55	<2 (mean 1.5)	3.5-0.55	35-67	80-100
PATIENT	6.8	NM	0.60	2.2	0.45	18	30
FELINE CARDIAC PARAMETERS	LA/AO (Boon)	LA/AO HEART BASE (Swe) (Abbott)	LA 2D short axis Base view (cm) (Abbott)	LVOT VEL (m/s)	RVOT VEL (m/s)	E max (m/s)	
NORMAL	<1.5	<1.3	<1.2	<1.6	<1.3	<0.9	
PATIENT	NM	>3.0	2.9	NM	NM	NM	

*Note: All measurements based upon multi-modal images and methods. An average value is reported.

Adapted from June Boon, Veterinary Echocardiography, 1998

Abbott J & MacLean H JVIM 2006;20: 111-119, Moise et al. Am J Vet Res 47:1476, 1986. Pipers et al. Am J Vet Res 40:882, 1979.

INTERPRETATION OF THE FINDINGS & FURTHER RECOMMENDATIONS

Unfortunately, this patient has end-stage cardiomyopathy and biventricular systolic dysfunction. The LV is highly asymmetric which may suggest prior infarcted regions. This is causing dilation and overload of all 4 chambers. The degree of dilation and pump failure is resulting in fulminant congestive heart failure, as seen with tricavitary effusion. Irregular tachycardia is noted throughout the study, and a baseline ECG is strongly recommended. It is important to note that this is not considered a complete study, likely due to patient instability. Further imaging may be warranted once the patient is stabilized.

In cats, systolic failure can be primary in nature (DCM); however, this is relatively uncommon. An advanced form of restrictive cardiomyopathy (RCM) with development of systolic dysfunction is also possible. Finally, systolic failure can develop secondary to taurine deficiency, myocarditis, or infiltrative disease such as lymphoma. Taurine deficiency is highly uncommon in cats on commercially prepared cat foods; however, can consider taurine supplementation in case of an absorption issue.

These findings support the diagnosis of congestive heart failure and immediate lifelong cardiac support is recommended as below. Thoracocentesis should be performed if needed. Prognosis is poor to grave at this stage in the disease process, with an average survival time of <6 months. Most cats are able to maintain a good QOL for some time however on oral medication. High risk



PATIENT

Mickey Morales

SPECIES

Feline

BREED

DSH

SEX

Male Neutered

AGE

9 years

WEIGHT

15lbs

INTERPRETED BY

Maggie Machen Lamy,
DVM, DACVIM
(Cardiology)

IMAGING PERFORMED BY

Elaina Petrone, DVM

HOSPITAL NAME

Long Branch Animal
Hospital

REFERRING VET

Dr. Petrone

INVOICE

45648

DATE

11/4/25

for recurrent CHF, development of blood clot events and/or malignant arrhythmias/sudden death at home should be discussed.

Monitor for development of labored breathing, limb paralysis/neurologic changes and/or collapse episodes in the future. Periodic thoracocentesis will be necessary going forward. Monitoring of sleeping breathing rates at home is recommended to assess response to medications and recurrence of CHF in the future.

PLAN

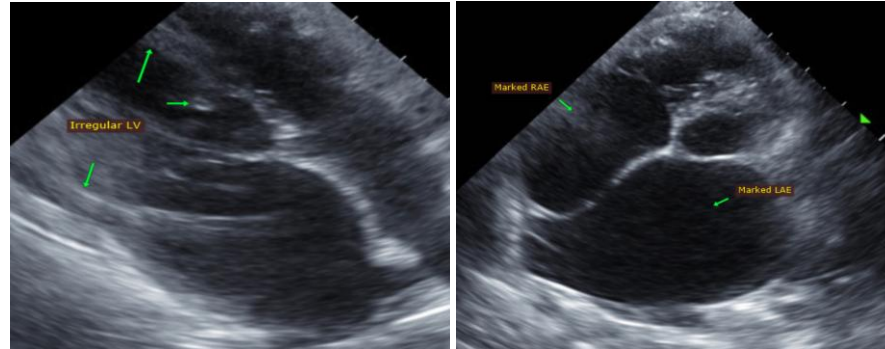
Baseline ECG recommended. Consider hospitalization/thoracocentesis for stabilization. Once stable, discharge on the following: Institute Lasix/furosemide 1-2mg/kg PO q12h. Institute anti-coagulant Plavix/Clopidogrel 75mg tabs; Give ¼ tab by mouth every 24 hours (NOTE: bitter along cut edge, may cause foaming at the mouth; coat in entirety). Institute heart muscle support Pimobendan 1.25mg by mouth every 12 hours (off label use). Consider supplement taurine 500mg daily.

Recheck renal panel and BP in 1-2 weeks then every 3-4 months lifelong. Do not utilize an ACEI in this patient. If patient continues to have respiratory changes at home, addition of spironolactone is recommended 1-2mg/kg PO q12h.

*NOTE: Many cats are difficult to medicate, and multiple medications can be overwhelming. If there is difficulty at home, Lasix and Plavix are considered most important. Consider compounding if needed.

Recheck echocardiogram in 6 months to reassess cardiac function.

IMAGES



The information and recommendations provided are based on the images presented by the referring veterinarian. No evaluation can be communicated regarding pathology that was not visible in the image/video clips provided.

Thank you for this referral. This report was generated using transcription software, and minor dictation errors may be present. If the clinical or image interpretation does not parallel your findings or if I can be of any further assistance, please contact me.

Maggie Machen Lamy, DVM
Diplomate of the American College of Veterinary Internal Medicine (Cardiology)
info@sonopath.com